

2016

Hematozoan Parasites (Apicomplexa, Kinetoplastida) of Seven Arkansas Reptiles (Testudines, Ophidia)

C. T. McAllister

Eastern Oklahoma State College, cmcallister@se.edu

M. B. Connior

Northwest Arkansas Community College

H. W. Robison

Southern Arkansas University

T. J. Fayton

University of Southern Mississippi

R. Tumilson

Henderson State University

See next page for additional authors

Follow this and additional works at: <http://scholarworks.uark.edu/jaas>

 Part of the [Zoology Commons](#)

Recommended Citation

McAllister, C. T.; Connior, M. B.; Robison, H. W.; Fayton, T. J.; Tumilson, R.; and Trauth, S. E. (2016) "Hematozoan Parasites (Apicomplexa, Kinetoplastida) of Seven Arkansas Reptiles (Testudines, Ophidia)," *Journal of the Arkansas Academy of Science*: Vol. 70 , Article 46.

Available at: <http://scholarworks.uark.edu/jaas/vol70/iss1/46>

This article is available for use under the Creative Commons license: Attribution-NoDerivatives 4.0 International (CC BY-ND 4.0). Users are able to read, download, copy, print, distribute, search, link to the full texts of these articles, or use them for any other lawful purpose, without asking prior permission from the publisher or the author.

This General Note is brought to you for free and open access by ScholarWorks@UARK. It has been accepted for inclusion in Journal of the Arkansas Academy of Science by an authorized editor of ScholarWorks@UARK. For more information, please contact scholar@uark.edu, ccmiddle@uark.edu.

Hematozoan Parasites (Apicomplexa, Kinetoplastida) of Seven Arkansas Reptiles (Testudines, Ophidia)

Authors

C. T. McAllister, M. B. Connior, H. W. Robison, T. J. Fayton, R. Tumilson, and S. E. Trauth

Hematozoan Parasites (Apicomplexa, Kinetoplastida) of Seven Arkansas Reptiles (Testudines, Ophidia)

C.T. McAllister^{1*}, M.B. Connior², H.W. Robison³, T.J. Fayton⁴, R. Tumilson⁵, and S.E. Trauth⁶

¹Science and Mathematics Division, Eastern Oklahoma State College, Idabel, OK 74745 ²Life Sciences, Northwest Arkansas Community College, Bentonville, AR 72712. ³Department of Biology, Southern Arkansas University, Magnolia, AR 71754-9354

⁴Gulf Coast Research Laboratory, University of Southern Mississippi, Ocean Springs, MS 39564

⁵Department of Biology, Henderson State University, Arkadelphia, AR 71999

⁶Department of Biological Sciences, Arkansas State University, State University, AR 72467

*Correspondence: cmcallister@se.edu

Running Title: Hematozoans of Arkansas Reptiles

Abstract

Little is known concerning the hematozoan parasites of Arkansas reptiles. Although there are previous reports in the state of these intraerythrocytic parasites infecting various reptiles, additional research is sorely needed. Here, we attempt to augment that void by providing additional hosts infected by these apicomplexans, including the first report of a trypanosome of a *Trypanosoma* sp. from an Arkansas turtle.

Introduction

Intraerythrocytic hematozoan parasites of the genera *Haemogregarina*, *Haemoproteus*, and *Hepatozoon* have been reported to infect various vertebrates, particularly reptiles (Telford 2009). Haemogregarines are most commonly reported from aquatic turtles with leeches serving as the only known invertebrate hosts and vectors (Telford 2009). In Arkansas, hematozoans have been reported from red-eared slider, *Trachemys scripta elegans* (McAllister and King 1980), diamondback watersnake, *Nerodia rhombifer*, western rat snake, *Pantherophis obsoletus obsoletus*, and western ribbon snake, *Thamnophis proximus proximus* (Daly et al. 1984), an alligator snapping turtle, *Macrochelys temminckii* (McAllister et al. 1995) and a common map turtle *Graptemys geographica* (McAllister et al. 2014). Here, we report new records for some hematozoans from 7 (5 turtles, 2 snakes) reptiles of the state, including photomicrographs and select measurements.

Methods

Between April 2012 and May 2015, we collected

the following 31 reptiles from Benton, Calhoun, Faulkner, Desha, Independence, Lincoln, Lonoke, Montgomery, Ouachita, Perry, Pulaski, Union, and White counties and examined them for hematozoans: **Testudines** – one eastern spiny softshell, *Apalone spinifera spinifera*, one common snapping turtle (*Chelydra serpentina*), one southern painted turtle (*Chrysemys dorsalis*), 4 Mississippi mud turtles (*Kinosternon subrubrum hippocrepis*), 2 eastern cooters (*Pseudemys concinna concinna*), one razorback musk turtle (*Sternotherus carinatus*), 7 common musk turtles (*Sternotherus odoratus*); **Ophidia** – 2 western cottonmouths (*Agkistrodon piscivorus leucostoma*), one each of green watersnake (*Nerodia cyclopion cyclopion*), broad-banded watersnake (*Nerodia fasciata confluens*), *N. rhombifer*, Midland watersnake, *Nerodia sipedon pleuralis*, *P. o. obsoletus*, 4 eastern garter snakes, *Thamnophis sirtalis sirtalis*, and 3 *T. p. proximus*. Turtles were collected with hoop traps baited with canned sardines or other fishes and snakes were taken with tongs or hand. Specimens were overdosed with an intraperitoneal injection of sodium pentobarbital (Nembutal®). Carapace length (CL) was measured for turtles and snout-vent length (SVL) taken for snakes. The plastron was removed from turtles with a bone saw. A mid-ventral incision was made on turtles and snakes to expose their hearts. Blood was obtained from the heart using ammonium heparinized (75 mm long) capillary tubes and thin films were air-dried, fixed for 1 min in absolute methanol, stained for 20–30 min with Wright-Giemsa stain, and rinsed in neutral-buffered phosphate buffer. Slides were scanned at 100× or 400× and when infected cells were found, photographs were taken and length measurements were made on most intraerythrocytic parasites (20/field) in red blood cells (rbcs) of select reptiles using a calibrated ocular micrometer under a

1,000× oil immersion lens and are reported in micrometers as means \pm 1SD followed by the ranges. Parasitemia levels are number of gamonts/1,000 erythrocytes counted. Host vouchers are deposited in the Arkansas State University Museum of Zoology (ASUMZ) Herpetological Collection, State University, Arkansas. Voucher slides of hematozoans are deposited in the Harold W. Manter Laboratory of Parasitology (HWML), Lincoln, Nebraska. Most reptile taxonomy follows Uetz and Hošek (2016); however, we follow Starkey et al. (2003) who elevated *C. p. dorsalis* to full species status.

Results and Discussion

Seven (50%) of the 14 individual reptile taxa, including *C. serpentina*, *C. dorsalis*, *K. s. hippocrepis*, *P. c. concinna*, *S. odoratus*, *A. p. leucostoma* and *T. p. proximus* were found to harbor hematozoans. The following were negative: 3 *K. s. hippocrepis*, 4 *S. odoratus*, 4 *T. s. sirtalis* and one each of *A. s. spinifera*, *P. c. concinna*, *S. carinatus*, *A. p. leucostoma*, *N. c. cyclopion*, *N. f. confluens*, *N. rhombifer*, *N. s. pleuralis*, and *P. o. obsoletus*. Overall prevalence with hematozoans was 10 of 31 (32%). Parasitemia in individual reptiles ranged from <1% to 10%. An average infection revealed 1–2 gamonts infected erythrocyte/20 microscopic fields. Data are presented below in an annotated format.

Apicomplexa: Adeleorina: Haemogregarinidae *Haemogregarina* sp. Danilewsky, 1885 (Fig. 1A–B)

Host: *Chelydra serpentina* (Linnaeus, 1758) – adult, not measured, collected 29 Jun. 2014.

Prevalence: 1 of 1 (100%).

Parasitemia: 5%.

Locality: Cane Creek Lake, Lincoln County, 33.96814°N, 94.804255°W).

Previous reports: The common snapping turtle is a widespread host of various hematozoans from specimens collected in Illinois, Iowa, Kentucky, Louisiana, Massachusetts, Nebraska, Ohio, Oklahoma, Tennessee, Texas, and Ontario, Canada (Hahn 1909, Roudabush and Coatney 1937, Edney 1949, Wang and Hopkins 1965, Marquardt 1966, Herban and Yeager 1969, Desser 1973, Acholonu 1974, Paterson and Desser 1976, McAuliffe 1977, Strohle and Christensen 1984, Siddall and Desser 1991, 2002, Brown et al. 1994, McAllister 2015).

Specimens deposited: HWML 101969.

Remarks: Kidney-bean shaped gamonts were most often observed (Fig. 1A) as well as infected rbc with

double gamonts (Fig. 1B). These gamonts ranged from 13.5 to 15.0 (mean 14.3 ± 0.3) μ m in length. The parasite nucleus is about half the size (7.0 μ m) of the gamont length and is situated in a polar position. Interestingly, McAllister (2015) recently reported a *C. serpentina* from Oklahoma showing a *Haemogregarina* sp. with similar morphology.

Haemogregarina sp. Danilewsky, 1885 (Fig. 1C–E)

Host: *Chrysemys dorsalis* Agassiz, 1857 – adult male, 118 mm CL, collected 17 Oct. 2014.

Prevalence: 1 of 1 (100%).

Parasitemia: 2%.

Locality: Kellogg Creek, just south of Jacksonville, Pulaski County (34.850581°N, 92.142688°W).

Previous reports (in C. dorsalis and/or C. picta): Florida (Langmann 1899), Georgia (Langmann 1899), Iowa (Roudabush and Coatney 1937), Massachusetts (Hahn 1909), Michigan (DeGuisti and Batten 1951), Nebraska (McAuliffe 1977), New York (Hahn 1909), Tennessee (Edney 1949), Wisconsin (DeGuisti and Batten 1951), London Zoological Gardens (Plimmer 1912), and Ontario, Canada (Siddall and Desser 2001, 2002).

Specimens deposited: HWML 101970.

Remarks: Kidney-bean shaped gamonts were short with a length of 12.5 ± 0.5 μ m. The nucleus of the parasite is compact and measures 4.3×3.4 μ m. A few elongate banana-shaped gamonts were observed but not measured. In addition, free merozoites (Fig. 1E) were seen.

Euglenozoa: Kinetoplastida: Trypanosomatidae *Trypanosoma* sp. Gruby, 1843 (Fig. 1F)

Host: *Chrysemys dorsalis* Agassiz, 1857 – adult male, 118 mm CL, collected 17 Oct. 2014.

Prevalence: 1 of 1 (100%).

Parasitemia: <1%.

Locality: Kellogg Creek, just S of Jacksonville, Pulaski County (34.850581°N, 92.142688°W).

Previous reports: None.

Specimens deposited: HWML 101970.

Remarks: What we believe to be a single trypomastigote of a *Trypanosoma* sp. was observed in this blood smear. Roudabush and Coatney (1937) described *Trypanosoma chrysemydis* from *Chrysemys picta* (and *C. serpentina*) from Iowa. In addition, Woo (1969) was able to infect *C. picta* (and other turtles) with *T. chrysemydis* by inoculation with crop and cecal contents of infected leeches, *Placobdella ornata* and *P. parasitica*. If confirmed, this represents the first report a trypanosome from *C. dorsalis*, and the first

Hematozoans of Arkansas Reptiles

trypanosome documented from an Arkansas vertebrate.

***Haemogregarina* sp. Danilewsky, 1885 (Fig. 1G)**

Host: *Kinosternon subrubrum hippocrepis* Gray, 1855 – adult female, 96 mm CL, collected 8 Apr. 2014.

Prevalence: 1 of 4 (25%).

Parasitemia: 5%.

Locality: Tulip Creek, off St. Hwy 7, Ouachita County (33.805019°N, 92.827807°W).

Previous reports: Louisiana (Herban and Yeager 1969), Texas (Wang and Hopkins 1965).

Specimens deposited: HWML101971.

Remarks: Small bean-shaped gamonts had length measurements of 13.0–15.0 μm , mean $14.2 \pm 0.3 \mu\text{m}$. The nucleus of the parasite is moderately-long and centrally located. In addition, free merozoites were also seen. We report a haemogregarine from an Arkansas *K. s. hippocrepis* for the first time.

***Haemogregarina* sp. Danilewsky, 1885 (Fig. 1H–I)**

Host: *Pseudemys concinna concinna* (Le Conte, 1830) – adult male, 175 mm CL, collected 13 Oct. 2015.

Prevalence: 1 of 2 (50%).

Parasitemia: 3%.

Locality: South Fork of the Fourche La Fave River near Hollis, Perry County (34.8706°N, 93.109458°W).

Previous reports: Louisiana (Herban and Yeager 1969, Acholonu 1974), Illinois (Marquardt 1966), Oklahoma (McAllister 2015), Tennessee (Edney 1949), Texas (Wang and Hopkins 1965).

Specimens deposited: HWML 101972.

Remarks: Bean-shaped gamonts measuring 14.5–17.0 μm (mean $16.3 \pm 0.3 \mu\text{m}$) appeared similar to those reported by McAllister (2015) from an eastern river cooter from Oklahoma.

***Haemogregarina* sp. Danilewsky, 1885 (Fig. 1J)**

Hosts: *Sternotherus odoratus* – 2 adult males, 1 adult female, 75–89 mm CL, collected 29–30 Jun. 2014.

Prevalence: 3 of 7 (43%).

Parasitemia: <1%.

Localities: Silver Lake, off St. Hwy 212, Desha County (33.973838°N, 91.436226°W); Cane Creek Lake, Lincoln County (34.091873°N, 94.739463°W).

Previous reports: Georgia (Davis and Sterrett 2011), Illinois (Marquardt 1966), Massachusetts, North Carolina (Hahn 1909).

Specimens deposited: HWML101973.

Remarks: Banana-shaped gamonts were most often observed in these common musk turtles but too few to measure.

Hepatozoidae

***Hepatozoon* sp. Miller, 1908 (Fig. 1K)**

Host: *Agkistrodon piscivorus leucostoma* Troost, 1836 – adult, not measured, collected 30 Jun. 2014.

Prevalence: 1 of 2 (50%).

Parasitemia: 10%.

Locality: Cane Creek Lake, Lincoln County (34.091873°N, 94.739463°W).

Previous reports: Florida (Langmann 1899, Laveran 1902), Louisiana (Marquardt and Yeager 1967, Acholonu 1969, Herban and Yeager 1969, Lowichik and Yeager 1987), Ohio (Zoo collection, Hull and Camin 1960), Quebec, Canada (Fantham and Porter 1954).

Specimens deposited: HWML 101974.

Remarks: Elongate long-slender gamonts with a curved tail were observed in erythrocytes of this cottonmouth. These ranged from 17.0–20.0 μm , mean $18.1 \pm 0.5 \mu\text{m}$ in length.

***Hepatozoon* sp. Miller, 1908 (Fig. 1L)**

Host: *Thamnophis proximus proximus* (Linnaeus, 1758) – adult male, 475 mm SVL, collected 5 Jul. 2014.

Prevalence: 1 of 3 (33%).

Parasitemia: 2%.

Locality: Spring Mill, Independence County (33.920662°N, 94.777173°W).

Previous reports: Arkansas (Daly et al. 1984), Iowa (Levine and Wacha 1983), Louisiana (Lowichik and Yeager 1987), New York (Langmann 1899), Pennsylvania (McKinstry 1973).

Specimens deposited: HWML101975.

Remarks: Daly et al. (1984, Fig. 1) shows an elongate *Hepatozoon* gamont from *T. p. proximus* from Arkansas similar to ones observed in the ribbon snake in the present study. Our elongate gamonts had length measurements of 17.0–20.0 μm , mean $18.0 \pm 0.6 \mu\text{m}$, similar to average length of 18.2 μm reported by Daly et al. (1984). In addition, Telford et al. (2004) reported *Hepatozoon sauritus* Telford, Wozniak and Butler from garter and ribbon snakes from Florida.

The differentiation of intraerythrocytic hematozoans by morphological types has been made on 2 Arkansas turtles, *T. s. elegans* by McAllister and King (1980) and *M. temminckii* by McAllister et al. (1995) using the characteristics of shape and general morphology of the parasite, measurement of the parasite nucleus (length and width), presence or absence of encapsulation, staining characteristics, and effect of the parasite on the host rbc. The latter characteristic includes hypertrophy of the host cell,

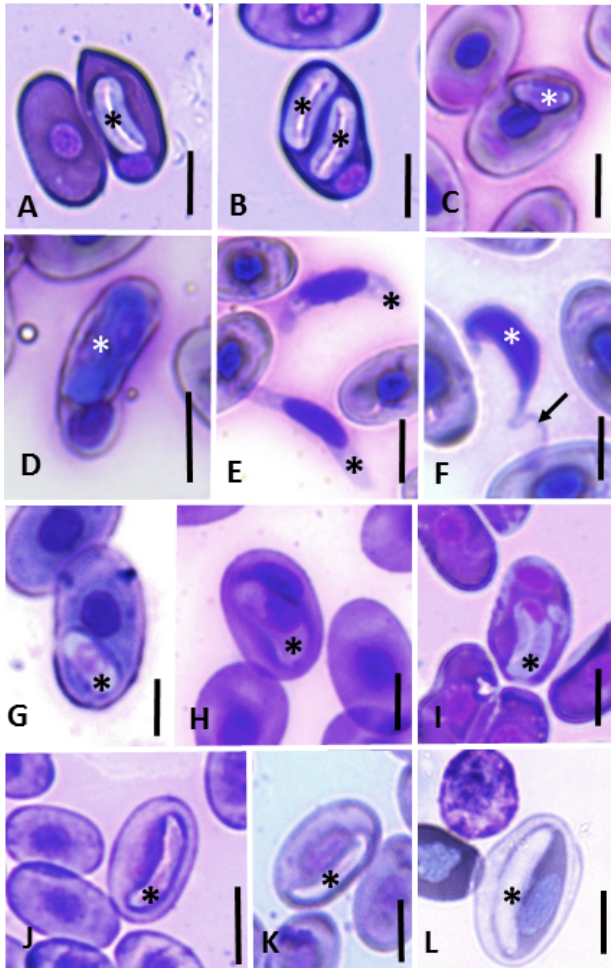


Figure 1. Hematozoan gamonts in rbc and a possible hemoflagellate from Arkansas reptiles (designated with an *). A. Bean-shaped gamont from *C. serpentina*. B. Two gamonts in single rbc from *C. serpentina*. C. Bean-shaped gamont from *C. dorsalis*. D. Banana-shaped gamont from *C. dorsalis*. E. Two free merozoites from *C. dorsalis*. F. Trypanosome? trypomastigote (*) from *C. dorsalis*. Arrow = flagella. G. Small bean-shaped gamont from *K. s. hippocrepis*. H. Bean-gamont form from *P. concinna*. I. Another bean-shaped gamont from *P. concinna*. J. Elongate gamont from *Sternotherus odoratus*. K. Elongate curved gamont from *A. p. leucostoma*. L. Elongate gamont from *T. p. proximus*. All scale bars = 10 μ m.

hemoglobin loss or displacement in the infected rbc, and change in the basic shape of the host cell. However, we consider staining a highly subjective evaluation that cannot be quantitated and would prefer to use this characteristic only in cases of obvious staining differences (see Daly et al. 1984). Using some of these criteria we were able to distinguish between 5 distinct types of hematozoan gamonts in the surveyed turtles and snakes as follows: (1) small bean-shaped, (2) large bean-shaped, (3) kidney bean-shaped, (4) banana-shaped, and (5) long elongate-shaped.

Although we document several Arkansas turtles

with what we feel are *Haemogregarina* spp., we suggest caution in their placement because the taxonomic identity of these hematozoans require knowledge of their complete life cycle including developmental stages in vector and definitive host leeches (Siddall and Desser 1991, 2001) and in hematophagous invertebrates (Jacobson 2007, Smith and Desser 1997). For hemogregarines in snakes, Smith (1996) considered all to be members of the genus *Hepatozoon* even in the absence of life-cycle data to the contrary. We therefore document the 2 hematozoans from Arkansas snakes herein to represent *Hepatozoon* spp.

The results of our survey indicate that hematozoan infections of turtles and snakes are relatively common in the state. That these intraerythrocytic parasites are ubiquitous in North American reptiles is supported by the survey results of other investigators who have reported prevalence ranging from 5 to 100%. Indeed, in one study, Wang and Hopkins (1965) found 75% of 44 turtles infected with *Haemogregarina* in Texas. And in other surveys, Lowichik and Yeager (1987) showed higher prevalence (96%) in 219 *A. p. leucostoma* collected in Sarpy Swamp, Louisiana, and Acholonu (1974) reported a prevalence of 100% for haemogregarines in turtles, also from Louisiana. In our own experience, we have found certain turtles and snakes (mostly aquatic to semi-aquatic species) to be more predictably infected with hematozoans than other herpetofauna (box turtles, lizards and smaller terrestrial snakes). It is obvious that conditions favoring infectivity of reptiles with hematozoans will vary depending on several ecological factors and the natural history of any potential host.

Reptiles are hosts of numerous described and potentially undescribed hematozoans (Ernst and Ernst 1979, Telford 2009). Arkansas supports 19 species and subspecies of turtles, 13 lizards, and 45 species and subspecies of snakes (Trauth et al. 2004). We suggest that future surveys seek to include a wider diversity and larger sample size of turtle, snake, and lizard hosts.

More importantly, inclusion of molecular approaches (DNA sequences) would be particularly helpful to identify some hematozoans (Allen et al. 2011, Cook et al. 2014, Maia et al. 2014) that are known with limited morphological traits. Therefore, we suggest that molecular approaches be used to elucidate the life cycles of these hematozoans, especially considering that this could potentially allow for their specific identification. Eventually, additional new host and distributional records should be found, including the possibility of discovering new species.

Hematozoans of Arkansas Reptiles

Acknowledgments

The Arkansas Game and Fish Commission issued Scientific Collecting Permits to us. We thank Scott L. Gardner (HWML) for expert curatorial assistance and James J. Daly, Sr., and to who first suggested to CTM that he should study hematozoa and whom we dedicate this paper. We also thank Vasyly V. Tkach (Univ. North Dakota) for assistance with processing some hosts on the Mac Dumas expedition in 2014.

Literature Cited

- Acholonu AD.** 1969. *Haemogregarina* (Sporozoa) in ophidians from Louisiana. Progress in Protozoology, abstracts of papers read at the IIIrd International Congress on Protozoology, Leningrad, 2-10 July 1969, p 331.
- Acholonu AD.** 1974. *Haemogregarina pseudemydis* n. sp. (Apicomplexa: Haemogregarinidae) and *Pirhemocytion chelonarum* n. sp. in turtles from Louisiana. Journal of Protozoology 21:659–664.
- Allen KE, MJ Yabsley, EM Johnson, MV Reichard, RJ Panciera, EA Ewing and SE Little.** 2011. Novel *Hepatozoon* in vertebrates from the southern United States. Journal of Parasitology 97:648–653.
- Brown GP, RJ Brooks, ME Siddall and SS Desser.** 1994. Parasites and reproductive output in the snapping turtle, *Chelydra serpentina*. Copeia 1994:228–231.
- Cook CA, SP Lawton, AJ Davies and NJ Smith.** 2014. Reassignment of the land tortoise haemogregarine *Haemogregarina fitzsimonsi* Dias 1953 (Adeleorina: Haemogregarinidae) to the genus *Hepatozoon* Miller 1908 (Adeleorina: Hepatozoidae) based on parasite morphology, life cycle and phylogenetic analysis of 18S rDNA sequence fragments. Parasitology 13:1–10.
- Daly JJ, RC McDaniel, JW Townsend and CH Calhoun Jr.** 1984. Alterations in the plasma membranes of *Hepatozoon*-infected snake erythrocytes as evidenced by differential staining. Journal of Parasitology 70:151–153.
- Davis AK and SC Sterrett.** 2011. Prevalence of haemogregarine parasites in three freshwater turtle species in a population in northeast Georgia, USA. International Journal of Zoological Research 7:156–163.
- DeGiusti DL and PJ Batten Jr.** 1951. Notes on *Haemoproteus metchnikovi* in turtles from Wisconsin, Michigan and Louisiana. Journal of Parasitology 37(Suppl.):12.
- Desser SS.** 1973. A description of intraerythrocytic schizonts and gametocytes of a haemogregarine of the snapping turtle *Chelydra serpentina*. Canadian Journal of Zoology 52:431–433.
- Edney JM.** 1949. *Haemogregarina stepanowi* Danilewsky (1885) in middle Tennessee turtles. Journal of the Tennessee Academy of Science 24:220–223.
- Ernst CH and EM Ernst.** 1979. Synopsis of protozoans parasitic in native turtles of the United States. Bulletin of the Maryland Herpetological Society 15:1–15.
- Fantham HB and A Porter.** 1954. The endoparasites of some North American snakes and their effects in the Ophidia. Proceedings of the Zoological Society of London 123:867–898.
- Hahn CW.** 1909. The stages of *Haemogregarina stepanovi* Danilewsky found in the blood of turtles, with special reference to changes in the nucleus. Archives für Protistenkunde 17:307–376.
- Herban NL and RG Yeager.** 1969. Blood parasites of certain Louisiana reptiles and amphibians. American Midland Naturalist 82:600–601.
- Hull RW and JH Camin.** 1960. Haemogregarines in snakes: The incidence and identity of the erythrocytic stages. Journal of Parasitology 46:515–523.
- Jacobson ER.** 2007. Parasites and parasitic diseases of reptiles. In: Jacobson ER (editor): Infectious diseases and pathology of reptiles: Color atlas and text. Boca Raton (FL): CRC Press, p. 571–576.
- Langmann G.** 1899. On hemosporidia in American reptiles and batrachians. New York Medical Journal 69:1–6.
- Levine ND and RS Wacha.** 1983. Haemogregarines (Protozoa, Apicomplexa) in Iowa reptiles. Journal of Protozoology 69:827.
- Lowichik A and RG Yeager.** 1987. Ecological aspects of snake hemogregarine infections from two habitats in southeastern Louisiana. Journal of Parasitology 73:1109–1115.
- Maia JP, A Crottini and DJ Harris.** 2014. Microscopic and molecular characterization of *Hepatozoon domerguei* (Apicomplexa) and *Foleyella furcata* (Nematoda) in wild endemic reptiles from Madagascar. Parasite 21:47–58.
- Marquardt WC.** 1966. Haemogregarines and *Haemoproteus* in some reptiles in southern Illinois. Journal of Parasitology 52:823–824.
- Marquardt WC and RG Yaeger.** 1967. Blood parasites of cottonmouth snakes from Louisiana. Programs and abstracts. Twentieth Annual Meeting of the Society of Protozoologists. Journal of Protozoology 14 (Suppl.):15–16.

- McAllister CT.** 2015. Hematozoa (Apicomplexa: Haemogregarinidae, Hepatozoidae) from two turtles (Testudines: Chelydridae, Emydidae) and two snakes (Ophidia: Colubridae, Viperidae), in southeastern Oklahoma. *Proceedings of the Oklahoma Academy of Science* 95:119–124.
- McAllister CT, CR Bursey, HW Robison, MB Connior and MA Barger.** 2014. *Haemogregarina* sp. (Apicomplexa: Haemogregarinidae), *Telorchis attenuata* (Digenea: Telorchidiidae) and *Neoechinorhynchus emydis* (Acanthocephala: Neoechinorhynchidae) from map turtles (*Graptemys* spp.), in northcentral Arkansas. *Journal of the Arkansas Academy of Science* 68:154–157.
- McAllister CT and AW King.** 1980. Hemogregarines in the red-eared slider, *Chrysemys scripta elegans* (Wied) from Arkansas. *Proceedings of the Arkansas Academy of Science* 34:124.
- McAllister CT, SJ Upton and SE Trauth.** 1995. Hemogregarines (Apicomplexa) and *Falcaustra chelydrae* (Nematoda) in an alligator snapping turtle, *Macroclemys temminckii* (Reptilia: Testudines), from Arkansas. *Journal of the Helminthological Society of Washington* 62:74–77.
- McAuliffe JR.** 1977. Hypothesis explaining variations of hemogregarine parasitemia in different aquatic turtle species. *Journal of Parasitology* 63:580–581.
- McKinstry DM.** 1973. Blood parasites in snakes of northwestern Pennsylvania. *Journal of Parasitology* 59:343.
- Paterson WB and SS Desser.** 1976. Observations of *Haemogregarina balli* sp. n. from the common snapping turtle, *Chelydra serpentina*. *Journal of Protozoology* 23:294–301.
- Plimmer HG.** 1912. On blood parasites found in animals in the Zoological Gardens during the four years 1907-1911. *Proceedings of the Zoological Society of London* 1:406–419.
- Roudabush RL and GR Coatney.** 1937. On some blood Protozoa of reptiles and amphibians. *Transactions of the American Microscopical Society* 56:291-297.
- Siddall ME and SS Desser.** 1991. Merogonic development of *Haemogregarina balli* (Apicomplexa: Adeleina: Haemogregarinidae) in the leech *Placobdella ornata* (Glossiphoniidae), its transmission to a chelonian intermediate host and phylogenetic implications. *Journal of Parasitology* 77:426–436.
- Siddall ME and SS Desser.** 2001. Transmission of *Haemogregarina balli* from painted turtles to snapping turtles through the leech *Placobdella ornata*. *Journal of Parasitology* 87:1217–1218.
- Siddall ME and SS Desser.** 2002. Prevalence and intensity of *Haemogregarina balli* (Apicomplexa: Adeleina: Haemogregarinidae) in three turtle species from Ontario, with observations on intraerythrocytic development. *Canadian Journal of Zoology* 70:123–128.
- Smith TG.** 1996. The genus *Hepatozoon* (Apicomplexa: Adeleina). *Journal of Parasitology* 82:565–585.
- Smith TG and SS Desser.** 1997. Phylogenetic analysis of the genus *Hepatozoon* Miller, 1908 (Apicomplexa: Adeleorina). *Systematic Parasitology* 36:213–221.
- Starkey DE, HB Shaffer, RL Burke, MR Forstner, JB Iverson, FJ Jansen, AG Rhodin and GR Ultsch.** 2003. Molecular systematics, phylogeography, and the effects of Pleistocene glaciation in the painted turtle (*Chrysemys picta* complex). *Evolution* 57:119–128.
- Strohlein DA and BM Christensen.** 1984. *Haemogregarina* sp. (Apicomplexa: Sporozoa) in aquatic turtles from Murphy's Pond, Kentucky. *Transactions of the American Microscopical Society* 103:98–101.
- Telford SR Jr.** 2009. Hemoparasites of the Reptilia: Color atlas and text. CRC Press (Boca Raton, Florida). 376 p.
- Telford SR Jr, JA Ernst, AM Clark and JF Butler.** 2004. *Hepatozoon sauritus*; A polytopic hemogregarine in three genera and four species of snakes in northern Florida, with specific identity verified from genome analysis. *Journal of Parasitology* 90:352–358.
- Trauth SE, HW Robison and M Plummer.** 2004. The amphibians and reptiles of Arkansas. University of Arkansas Press (Fayetteville). 421 p.
- Uetz P and J Hošek.** 2016. The TIGR Reptile Database. World Wide Web electronic publication. <http://www.reptile-database.org/>. Accessed 18 February 2016.
- Wang CC and SH Hopkins.** 1965. *Haemogregarina* and *Haemoproteus* (Protozoa, Sporozoa) in blood of Texas freshwater turtles. *Journal of Parasitology* 51:781–787.
- Woo PTK.** 1969. The life cycle of *Trypanosoma chrysemydis*. *Canadian Journal of Zoology* 47:1139–1151.