

2005

## Abnormalities in the Ozark Hellbender, (*Cryptobranchus alleganiensis bishopi*) in Arkansas: A Comparison Between Two Rivers with a Historical Perspective

Waylon R. Hiler  
*Arkansas State University*

Benjamin A. Wheeler  
*Arkansas State University*

Stanley E. Trauth  
*Arkansas State University*, [trauthse@outlook.com](mailto:trauthse@outlook.com)

Follow this and additional works at: <https://scholarworks.uark.edu/jaas>



Part of the [Zoology Commons](#)

---

### Recommended Citation

Hiler, Waylon R.; Wheeler, Benjamin A.; and Trauth, Stanley E. (2005) "Abnormalities in the Ozark Hellbender, (*Cryptobranchus alleganiensis bishopi*) in Arkansas: A Comparison Between Two Rivers with a Historical Perspective," *Journal of the Arkansas Academy of Science*: Vol. 59, Article 13.

Available at: <https://scholarworks.uark.edu/jaas/vol59/iss1/13>

This article is available for use under the Creative Commons license: Attribution-NoDerivatives 4.0 International (CC BY-ND 4.0). Users are able to read, download, copy, print, distribute, search, link to the full texts of these articles, or use them for any other lawful purpose, without asking prior permission from the publisher or the author.

This Article is brought to you for free and open access by ScholarWorks@UARK. It has been accepted for inclusion in *Journal of the Arkansas Academy of Science* by an authorized editor of ScholarWorks@UARK. For more information, please contact [scholar@uark.edu](mailto:scholar@uark.edu), [uarepos@uark.edu](mailto:uarepos@uark.edu).

# Abnormalities in the Ozark Hellbender (*Cryptobranchus alleganiensis bishopi*) in Arkansas: A Comparison between Two Rivers with a Historical Perspective

WAYLON R. HILER<sup>1</sup>, BENJAMIN A. WHEELER<sup>2</sup> AND STANLEY E. TRAUTH<sup>1,3</sup>

<sup>1</sup>Department of Biological Sciences, Arkansas State University, P.O. Box 599, State University, AR 72467

<sup>2</sup>Environmental Sciences Program, Arkansas State University, P.O. Box 847, State University, AR 72467

<sup>3</sup>Correspondent: [strauth@astate.edu](mailto:strauth@astate.edu)

## Abstract

We documented abnormalities of Ozark hellbender (*Cryptobranchus alleganiensis bishopi*) populations in the Eleven Point River (Randolph County, Arkansas) and the Spring River (Fulton County, Arkansas) as part of ongoing monitoring efforts in this species. We found abnormalities in 90% (9 of 10) and 40% (36 of 97) of hellbenders in the Spring River and Eleven Point River, respectively, during the 2003-2004 field seasons. Most abnormalities found in Eleven Point hellbenders were generally less invasive and seemed to be more intrinsic to the species' natural history (i.e., vicissitudes of living), whereas those found in Spring River hellbenders were gross morphological aberrations. We compared the type and rate of observed abnormalities with those found in museum vouchers collected from the Spring River between 1970 and 1975. Abnormalities were found in 12.5% of the museum specimens from our Spring River localities. This rate is much higher than previously reported for hellbenders. The increase in the abnormality rate appears to be concurrent with the documented population decline observed in the Spring River. Our study illustrates an increasing trend of hellbenders exhibiting unusual morphological problems (e.g., epidermal papillomas, extreme abrasions/lacerations, fungal infections, etc.) and also stresses the need for inclusion of abnormalities observed in field data. The causes of hellbender abnormalities remain speculative; however, plausible explanations may be related to intraspecific interactions, anthropogenic interactions with the microhabitat, viral infections, non-point/point source pollution, and the preponderance of older individuals. These findings emphasize the need for a proactive conservation effort within this species.

## Introduction

The Ozark hellbender (*Cryptobranchus alleganiensis bishopi*) is a large, permanently aquatic salamander that is endemic to five south flowing rivers in Missouri and northern Arkansas (Firschein, 1951). Two rivers in Arkansas known to have populations of hellbenders are the Spring River (Nickerson and Mays, 1973; Peterson, 1985) and Eleven Point River (Trauth et al., 1993). Since the early 1980's, Ozark hellbender populations have undergone decline throughout the entire range (Trauth et al., 1992; Wheeler et al., 2003). In Arkansas, the Spring River population has had the most drastic decline witnessed over the past 20 years (Trauth et al., 1992; W. Hiler, unpubl. data). Currently, the U.S. Fish and Wildlife Service lists the Ozark hellbender as an Endangered Species Candidate (Federal Register, 2001), and the species is protected from collection, at the state level, in both Arkansas and Missouri.

Population declines in this species are characterized by fewer small individuals (an indication of reduced recruitment—Wheeler et al., 2003), a lower capture rate (Trauth et al., 1992; Wheeler et al., 2003), loss of historic habitats (Trauth et al., 1993), and high abnormality rates (Wheeler et al., 2002) compared to historical data. Potential causes of declines include interactions with non-native

(stocked) species, poor land management, reduction in the riparian zone, urban development, heavy human traffic on and through riverine habitat, and over/illegal collection (Bartlett, 1988; Trauth et al., 1992, 1993; Federal Registry, 2001; Wheeler et al., 2003). These causes remain speculative and are especially difficult to quantify for the Spring River due to the drastic depression in current hellbender numbers. We feel it is realistic to examine the differences between a river which harbors a relatively stable population of hellbenders (the Eleven Point) and Spring River whose hellbender population is essentially extirpated. One condition that has yet to be compared between rivers is occurrence of abnormalities.

The objectives of this study were to describe the types of abnormalities and quantify their rates within the Eleven Point and Spring rivers and museum specimens from the Spring River which may provide a historical perspective on abnormality rates.

## Materials and Methods

Detailed documentation of abnormalities began in August 2003 and continued through December 2004. Hellbenders (n = 10) examined in this study were collected from three locations in the Spring River (Fulton County),

Arkansas. We found hellbenders ( $n = 96$ ) at 20 locations in the Eleven Point River from the Arkansas/Missouri state line to just north of the Arkansas State Highway 90 bridge. We also examined 47 hellbenders from the Milwaukee Public Museum collected from the Spring River during the early-to-mid 1970s.

Hellbenders were collected using standard rock-flipping techniques, while either scuba or skin diving. The total length (TL), snout-vent length (SVL) to the anterior end of the cloacal opening, mass, and sex were recorded for each individual. An encrypted (AVID® Identification Systems, Inc., Norco, CA) passive integrated transponder (PIT) tag was implanted in the dorsal musculature of the tail immediately posterior to the hind limbs for unique identification. Abnormalities were documented in our field notes, described morphologically based on their gross appearance, and were photographed with a Sony® CD Mavica 5.0 megapixel camera. Abnormalities were then grouped into the following categories: 1) tumors, 2) open wounds, 3) fungal infections, 4) necrotic limbs, 5) missing limbs, 6) digital abnormalities, 7) eye abnormalities, 8) cloacal wounds, and 9) bite marks.

## Results

Our examinations revealed 24 abnormalities in 9 of 10 (90%) of the Spring River animals during 2003–2004 sampling periods. Six of 9 exhibited multiple abnormalities. We found 59 abnormalities in 38 of 96 (40%) animals encountered in the Eleven Point River throughout the 2003–2004 field seasons. Only 23% of the hellbenders in Eleven Point River sample exhibited multiple abnormalities. Of the 47 Spring River museum specimens, 6 (12.5%) exhibited abnormalities (one per individual). In the following, we characterize the types of abnormalities observed.

**Tumors.**—Neoplasms included epidermal papillomas and tumor-like, small white nodules with diameters of ca. 2–3 mm (see Trauth et al., 2002; Fig. 1A). Tumors were documented in 3 Spring River hellbenders (12.5% of total abnormalities [= TA]), 1 Eleven Point animal (1.5% of TA), and 1 Spring River museum specimen (16.5% of TA). A Spring River female captured below the Arkansas State Highway 63 bridge contained multiple epidermal papillomas and subsequently died during transport to the laboratory for tumor biopsy.

**Open Wounds.**—These abnormalities included minor-to-severe gashes, abrasions, and lacerations. Six hellbenders with (25.0% of TA) sores, lesions, and lacerations were documented in the Spring River, one (1.5% of TA) in the Eleven Point River, and 2 (33.3% of TA) identified in the museum specimens. One individual captured below Dam 3 exhibited an enlarged ovoid ulcer on the lower jaw ca. 20 mm in diameter (Fig. 1B). Another animal had multiple,

severe gashes which began just above the right shoulder and extended in an anterior to posterior direction on the dorsum (Fig. 1C). These wounds appeared to be the result of a gigning or snagging incident and showed signs of a fungal resistance. The Spring River female with epidermal papillomas also displayed extensive abrasions along the lower jaw which showed no signs of healing (Fig. 1D).

**Fungal Infections.**—Fungal infections were only found on 1 Spring River hellbender. In addition to its dorsal fungal infection, this individual exhibited an oral infection on the tongue (ca. 20 mm in diameter; Fig. 1E) and another on the palm of the left rear foot (Fig. 1F). This hellbender also had a fingernail clam (*Sphaerium* sp.) as well as a leach (Fig. 1F) attached to the left rear limb. Fungal infections comprised 12.5% of the TA observed in the Spring River.

**Necrotic Limb(s).**—Necrotic limbs were characterized by “worn palms” exhibiting exposed musculature and, in some cases, exposed bone (see Wheeler et al., 2002). Necrotic limbs comprised 20.8% of TA documented in the Spring River and 13.5% of those in the Eleven Point River. No museum specimens exhibited this abnormality. Typically, the epidermis surrounding the open flesh appeared to be dead and peeling away from the wound. Protruding bone from flesh was less common than simple bone exposure at the center of the necrotic limb.

**Missing Limb(s).**—Missing limbs (see Wheeler et al., 2002) were distinguished by the absence of all tarsal and/or carpal regions. Missing limbs represented 20.8% of all abnormalities in the Spring River and 17.0% in the Eleven Point River. No cases museum specimens had missing limbs. In some cases, limbs had healed and epidermal tissue covered the entire appendage. In several instances remnants of digits remained attached to the limb. Individuals missing multiple limbs were not as common as those missing 1 limb.

**Digital Abnormalities.**—Missing, fused, or supernumerary digits (see Wheeler et al., 2002) were the most common abnormalities found in Eleven Point hellbenders. Digital abnormalities represented 12.5% of TA in the Spring River, 51.0% in the Eleven Point River, and 33.3% in the museum specimens. Typically, there was no sign of amputation of the digit, only the physical absence. Fused digits were 2 digits fused by epidermal tissue and lack any of open wound.

**Eye Abnormalities.**—Eye abnormalities were fairly uncommon and only documented in 2 (3.4% of TA) Eleven Point River hellbenders. Both occurrences were characterized by the presence of a small opaque piece of tissue protruding from an eye.

**Cloacal Wounds.**—One Eleven Point River male hellbender was missing a cloacal lip (1.5% of TA), and a moderate amount of scarring overlay the afflicted area. The animal was captured on 11 September, 2004, just before the breeding season and the intact lip was swollen, typical of reproductively active males. This male and other males

## Abnormalities in the Ozark Hellbender (*Cryptobranchus alleganiensis bishopi*) in Arkansas: A Comparison between Two Rivers with a Historical Perspective

were not leaking milt. This type of wound has been observed in other individuals (B. A. Wheeler, unpubl. data).

**Bite Marks.**—Bite marks were characterized by open wounds or scarring patterns matching the dentition of another hellbender (Fig. 2). These wounds appeared on various parts of the body. We captured several individuals with wounds on appendages, apparently caused by a slicing action from the teeth of another hellbender (Fig. 2E and 2F). Bite marks were not documented in any Spring River hellbenders; however, they comprised 10% of TA in the Eleven Point River and 16.5% in museum specimens.

### Discussion

Physical abnormalities in hellbender populations are known throughout their range (Nickerson and Mays, 1973; Pflingsten, 1990), but have received little attention in the literature. Pflingsten (1990) was the first to quantify abnormality rates within hellbender populations and reported abnormality rates which exceeded those expected to occur naturally (Johnson et al., 1999; Kaiser, 1999). Wheeler et al. (2002) documented an 8% abnormality rate throughout 12 years of sampling Ozark hellbenders in three rivers. They noted that no consistent effort was made to record every abnormality observed in the field, and they also did not compare different river systems. Our findings indicate the relatively low rate reported by Wheeler et al. (2002) is not an accurate assessment of the actual condition within individual populations. This illustrates the necessity of acquiring detailed field data including observations of injuries and abnormalities.

Most abnormalities found in Eleven Point River hellbenders were generally less conspicuous and appeared to be more related to the species' natural history, whereas those found in Spring River hellbenders were gross morphological aberrations. Over one half (51.0%) of the abnormalities in the Eleven Point River were digital abnormalities, whereas only 12.5% with this type of abnormality were observed in the Spring River. The proportion of hellbenders missing limbs was similar, 17.0% versus 20.8%, in the Eleven Point River and the Spring River, respectively. Numerous aspects of a hellbender's life history could make them susceptible to these types of injuries. Through time, older animals in the Spring River might have a greater chance to accumulate digital injuries which can be masked by missing limbs.

When comparing the number of abnormalities per individual, Spring River rates are much greater than those in the Eleven Point River. In the Eleven Point River, the multiple abnormalities primarily consisted of digital injuries and missing limbs, whereas the Spring River abnormalities were a mixture of all types. The chance of acquiring an abnormality probably increases through time. As age increases there may be decreases in immune efficiency

which in turn may leave individuals more susceptible to viral (i.e., epidermal papillomas) and fungal infections.

All fresh bite marks were observed during the fall (reproductive season) on individuals from Eleven Point River animals. Pflingsten (1990) also documented fresh bite marks only during August and September (the reproductive season in Ohio). We concur with Wheeler et al. (2002) and Pflingsten (1990) in suggesting that intraspecific aggression may be the cause of limb injuries. This behavior implies territoriality and can be attributed to the establishment of nesting cavity by males (Nickerson and Mays, 1973). We, therefore, suggest that the presence of bite marks on animals in the Eleven Point River is indicative of reproductive behavior.

The bite marks present in the Eleven Point hellbenders were not exhibited on present day Spring River hellbenders, and this may indicate a decrease in antagonistic behavior among individuals. Only 1 hellbender examined from Spring River museum animals had scar tissue from bites. Habitat loss or fragmentation, a situation now present in the Spring River, could isolate individuals and reduce interactions among hellbenders. Another possibility could be low population numbers which should reduce the number of territoriality interactions and perhaps their intensity.

To further understand the implications of the current abnormality rates, we gathered historic data from museum records as well as raw field data not presented in Nickerson and Mays (1973). Nickerson (pers. comm.) found a 2.3% abnormality rate in hellbenders ( $n = 479$ ) from the North Fork of the White River, Missouri, while making an effort to record each abnormality. If we assume that abnormalities occur equally throughout and across all populations, then we can further assume that the 2.3% found by Nickerson would be the expected rate found in a healthy population. Museum specimens collected from the Spring River prior to 1975 (presumably before the current population decline) showed a 12.5% abnormality rate. Today, the rate for the Spring River is 90%. This observed increase appears to be concurrent with the documented population decline observed in the Spring River. We can, therefore, postulate that the elevated rate in museum specimens is indicative of the beginning stage of the Spring River population decline as mentioned by Trauth et al. (1992). At present, the Eleven Point River has a 40% abnormality rate and may already be in jeopardy of undergoing a similar decline.

The severe nature of the abnormalities observed in the Spring River may be cause for concern. For example, the open wounds shown in Fig. 1B and D have no known causes and appear to be life threatening. The tumorous animal reported by Trauth et al. (2002) was only the second reported occurrence found within *Cryptobranchus*. We observed an additional 5 animals with tumors in our study.

Historically, the Spring River has received the most

publicity and has been recognized as a unique river system in Arkansas inhabited by hellbenders (Nickerson and Mays, 1973; Peterson, 1985; Peterson et al., 1988, 1989a, 1989b; Trauth et al., 1992; Wheeler et al., 2002). The river itself, and its tributaries, have been designated as Extraordinary Resource Waters by the Arkansas Pollution Control and Ecology Commission (APCEC, 2004), indicating that the drainage is an invaluable resource for recreational activities as well as science. The Spring River has also been designated as an ecologically sensitive water body by APCEC, indicating that the river harbors rare, threatened, endangered, or endemic species. These features as well as numerous other unique characters make this river an important ecological asset for Arkansas.

### **Conclusions**

The specific causes of hellbender abnormalities remain speculative; still, we feel that there are several factors which may influence these abnormality rates. First, we contend that human interactions may disrupt hellbender microhabitat and indirectly lead to some abnormalities or even mortality. These activities include gigging, snagging, and wade fishing. Secondly, intraspecific interactions such as antagonistic behavior, including biting, undoubtedly lead to appendage aberrations. It is also plausible that the most severe

abnormalities would be most conspicuous in older individuals and would be more frequently observed or expressed in a greater percentage in senescent populations similar to those in the Spring River. We realize that there are other factors that may cause abnormalities and assume that most abnormalities are not directly influencing the observed population declines. However, increasing abnormalities are occurring concurrently with these declines. Hellbenders live in many streams which have substantial human activity. The very characteristics that make these river systems important recreationally are the same features that have been neglected ecologically. This disregard in the Spring River's ecological health is evident in the current status of the Ozark hellbender population.

**ACKNOWLEDGMENTS.**—We thank the Arkansas Game and Fish Commission (Kelly Irwin), Mammoth Spring National Fish Hatchery (Richard Shelton and Dewayne French), Jim Hinkle State Fish Hatchery, the Milwaukee Public Museum (Dr. Gary Casper) and Woody King for support during this project. We also thank Dr. Max A. Nickerson for his unpublished data and the many fellow researchers that assisted in the collection of field data. Collection of data was authorized under Scientific Collection Permit No. 041420042 to SET.

Abnormalities in the Ozark Hellbender (*Cryptobranchus alleganiensis bishopi*) in Arkansas:  
A Comparison between Two Rivers with a Historical Perspective

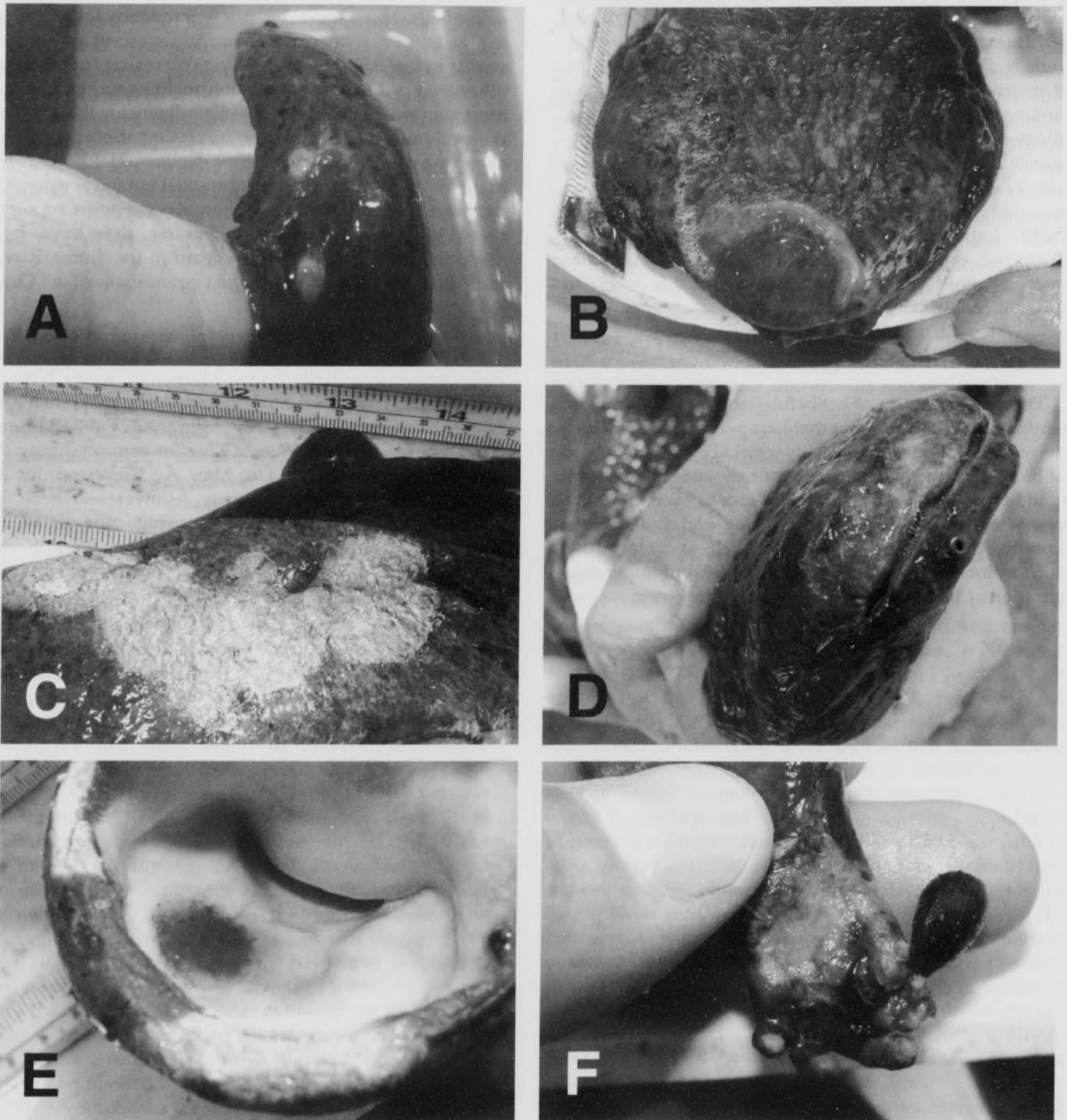


Fig. 1. Abnormalities observed in the Ozark hellbender from the Spring River (Fulton County), Arkansas, during 2003-2004 sampling period. A. Epidermal nodules on lateral surface of tail. B. Highly vascularized, circular cyst on the lower jaw. C. Large dorsal wounds posterior to head with massive fungal infection. D. Extensive abrasion around mental symphysis. E. Oral fungal infection. F. Left hind limb with fungal infection, leech attached to palm, and fingernail clam (*Sphaerium* sp.) attached to digit.

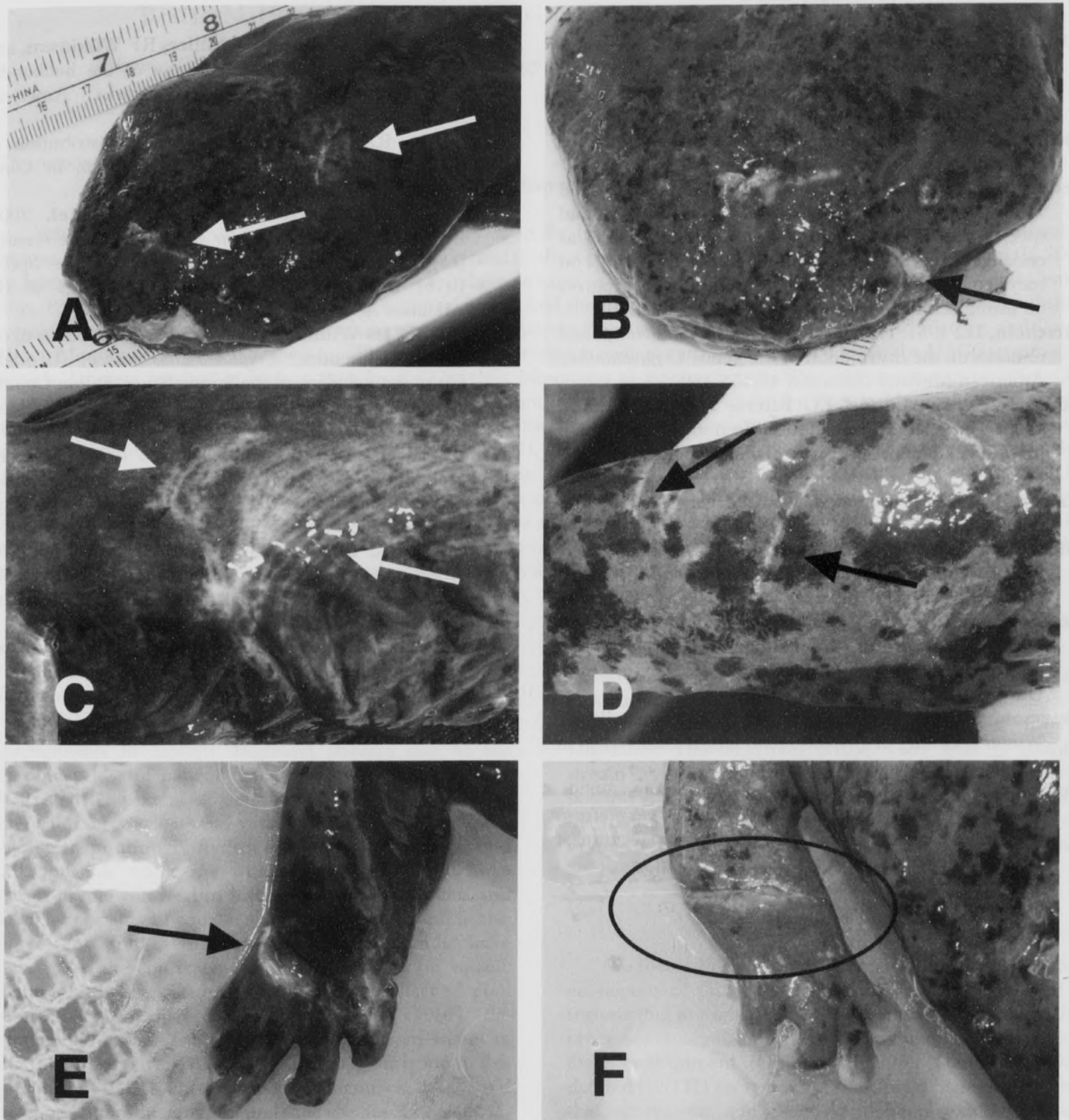


Fig. 2. Bite marks resulting from intraspecific aggression in the Ozark hellbender (Eleven Point River, Randolph County, Arkansas) during the 2003-2004 sampling period. A and B. Arrows point to wounds on head and snout. C and D. Arrows point to a series of semicircular scars on separate individuals, each caused by a single encounter with another hellbender (C, on abdomen; D, on tail). E and F. Arrow points to wound encircling entire limb; circled area in F highlights linear wound across limb.

**Abnormalities in the Ozark Hellbender (*Cryptobranchus alleganiensis bishopi*) in Arkansas:  
A Comparison between Two Rivers with a Historical Perspective**

**Literature Cited**

- APCEC.** 2004. Regulation 2: Regulation establishing water quality standards for surface waters of the state of Arkansas. Arkansas Pollution Control and Ecology Commission, April 23, 2004.
- Bartlett, RD.** 1988. In search of reptiles and amphibians. E.J. Brill, New York, NY.
- Federal Register.** 2001. Endangered and threatened wildlife and plants; Review of plant and animal species that are candidates or proposed for listing as endangered or threatened, annual notice of findings on recycled petitions, and annual description of progress on listing actions; Proposed rule. October 30, 2001.
- Firschein, IL.** 1951. The range of *Cryptobranchus bishopi* and remarks on the distribution of the genus *Cryptobranchus*. American Midland Naturalist 45:455-459.
- Johnson, PT, KB Lunde, EG Ritchie and, AE Launer.** 1999. The effect of trematode infection on amphibian limb development and survivorship. Science 284:802-804.
- Kaiser, J.** 1999. A trematode parasite causes some frog deformities. Science 284:731-733.
- Nickerson, MA, and CE Mays.** 1973. The hellbender: North American "giant salamanders." Milwaukee Public Museum 1:1-106.
- Peterson, CL.** 1985. Comparative demography of four populations of the hellbender, *Cryptobranchus alleganiensis*, in the Ozarks. Ph. D. Dissertation. University Missouri, Columbia, 158 pp.
- Peterson, CL, CA Ingersol, and RF Wilkinson.** 1989a. Winter breeding of *Cryptobranchus alleganiensis bishopi* in Arkansas. Copeia 1989:1031-1035.
- Peterson, CL, J W Reed, and RF Wilkinson.** 1989b. Seasonal food habits of *Cryptobranchus alleganiensis* (Caudata: Cryptobranchidae). Southwestern Naturalist 34:438-441.
- Peterson, CL, DE Metter, BT Miller, RF Wilkinson, and MS Topping.** 1988. Demography of the hellbender *Cryptobranchus alleganiensis* in the Ozarks. American Midland Naturalist 119:291-303.
- Pfingsten, RA.** 1990. The status and distribution of the hellbender, *Cryptobranchus alleganiensis*, in Ohio. Herpetological Review 21:48-51.
- Trauth, SE, JC Harshbarger, and P Daniel.** 2002. Epidermal papillomas in an Ozark hellbender (*Cryptobranchus alleganiensis bishopi*) from the Spring River of northern Arkansas. Proceedings of the Arkansas Academy Science 56:190-197.
- Trauth, SE, JD Wilhide, and P Daniel.** 1992. Status of the Ozark hellbender, *Cryptobranchus bishopi* (Urodela: Cryptobranchidae), in the Spring River, Fulton County, Arkansas. Proceedings of the Arkansas Academy Science 46:83-86.
- Trauth, SE, JD Wilhide, and P Daniel.** 1993. The Ozark Hellbender, *Cryptobranchus bishopi*, in Arkansas: distributional survey for 1992. Bulletin of the Chicago Herpetological Society 28:81-85.
- Wheeler, BA, ML McCallum, and SE Trauth.** 2002. Abnormalities in the Ozark hellbender, *Cryptobranchus alleganiensis bishopi*. Journal of the Arkansas Academy Science 56:250-52.
- Wheeler, BA, E Prosen, A Mathis, and RF Wilkinson.** 2003. Population declines of a long-lived salamander: a 20+ year study of hellbenders, *Cryptobranchus alleganiensis*. Biological Conservation 109:151-156.