

2018

Prevalence of *Cytauxzoon felis* (Protista: Apicomplexa) in Feral Cats in Russellville Arkansas

Cynthia H. Jacobs

Arkansas Tech University, cjacobs@atu.edu

Follow this and additional works at: <https://scholarworks.uark.edu/jaas>

 Part of the [Veterinary Infectious Diseases Commons](#), and the [Veterinary Preventive Medicine, Epidemiology, and Public Health Commons](#)

Recommended Citation

Jacobs, Cynthia H. (2018) "Prevalence of *Cytauxzoon felis* (Protista: Apicomplexa) in Feral Cats in Russellville Arkansas," *Journal of the Arkansas Academy of Science*: Vol. 72 , Article 21.

Available at: <https://scholarworks.uark.edu/jaas/vol72/iss1/21>

This article is available for use under the Creative Commons license: Attribution-NoDerivatives 4.0 International (CC BY-ND 4.0). Users are able to read, download, copy, print, distribute, search, link to the full texts of these articles, or use them for any other lawful purpose, without asking prior permission from the publisher or the author.

This Article is brought to you for free and open access by ScholarWorks@UARK. It has been accepted for inclusion in Journal of the Arkansas Academy of Science by an authorized editor of ScholarWorks@UARK. For more information, please contact scholar@uark.edu, ccmiddle@uark.edu.

Prevalence of *Cytauxzoon felis* (Protista: Apicomplexa) in Feral Cats in Russellville Arkansas

C.H. Jacobs

Department of Biological Sciences, Arkansas Tech University, Russellville, AR 72801

Correspondence: cjacobs@atu.edu

Running title: Prevalence of *Cytauxzoon felis* in Feral Cats

Abstract

Cytauxzoon felis (*C. felis*) is a protozoan hemoparasite of domestic and wild felids. Transmitted by ixodid ticks, the sylvatic reservoir for this organism in North America is the bobcat (*Lynx rufus*) in which the infection is apparently self-limiting. In domestic cats (*Felis catus*), *C. felis* causes a highly fatal disease with a distribution that covers much of the central, southcentral and southeastern U.S. and parallels that of the primary vector, the lone star tick (*Amblyomma americanum*). Interestingly, there appears to be an increased survival rate in domestic cats in the geographic area of the Ozark Plateau. In this study, convenience blood samples from apparently healthy feral cats were microscopically evaluated for the presence of *C. felis* merozoites. Positive samples were submitted for PCR confirmation by a commercial laboratory. Results indicated a prevalence of 13% (4/32) in this population. Understanding the prevalence of *C. felis* infection in feral cats is central to evaluating their potential role as a reservoir for the disease and may also further our understanding about the variable pathogenicity of this organism.

Introduction

Cytauxzoonosis is a hemoparasitic infection of felids that is characterized by a rapid course of disease with a high morbidity and mortality in the domestic cat (*Felis catus*). First reported in North America in Missouri (Wagner 1976) this emerging disease has since been identified in wild and domestic felids from the Midwest to the mid-Atlantic states in the U.S. (Birkenheuer *et al.* 2006a; Haber *et al.* 2007; Shock *et al.* 2011; Tarigo *et al.* 2013; Zieman *et al.* 2017). Cytauxzoonosis is caused by an apicomplexan hematozoan parasite, *Cytauxzoon felis* (*C. felis*), that is transmitted by ixodid (hard shell) ticks. Although *C. felis* is thought to infect felids only, a closely related genus *Babesia* causes tick-borne disease in a wide

variety of vertebrate hosts, including man. Thus *C. felis* belongs to a family of hemoparasites that has agricultural and zoonotic importance worldwide (Alvarado-Rybak *et al.* 2016; Wang *et al.* 2017). In the United States the principal vector of *C. felis* appears to be the lone star tick (*Amblyomma americanum*) (Reichard *et al.* 2009). The American dog tick (*Dermacentor variabilis*) is also known to carry the protozoan, but its ability to transmit the disease may be limited (Reichard *et al.* 2009). Both vectors have extensive ranges that overlap with the current distribution of *C. felis*. Both tick vectors are found in Arkansas (McAllister *et al.* 2016).

In North America, the bobcat (*Lynx rufus*) is the primary sylvatic reservoir for this parasite. The reported prevalence of infection in bobcats ranges from 7-70% (Birkenheuer *et al.* 2008; Shock *et al.* 2011; Zieman *et al.* 2017) and the natural infection in these animals is apparently self-limiting and asymptomatic. In the domestic cat, on the other hand, the course of disease is rapid and highly fatal. Clinical signs of cytauxzoonosis are non-specific and typically include acute onset of fever, inappetance, lethargy or weakness, palor, icterus, and/or respiratory distress. Death occurs as a result of multiple organ failure caused by widespread vascular occlusion. With treatment, a 60% survival has been reported (Cohn *et al.* 2011). Thus the domestic cat has historically been considered to be an aberrant or dead-end host.

The life cycle of *C. felis* is complex involving sexual reproduction within the tick vector, as well as asexual replication (schizogony, or merogony) in the felid host (Fig. 1). The red blood cell inclusions, called merozoites, are the basis of the cytological screening test for the disease. Domestic cats that manage to survive the acute schizogenous phase of the disease do not completely clear the organism from their system. Instead they become chronic carriers and a potential reservoir for the parasite. In these animals, a low level parasitemia may persist for years following natural infection (Brown *et al.* 2008).

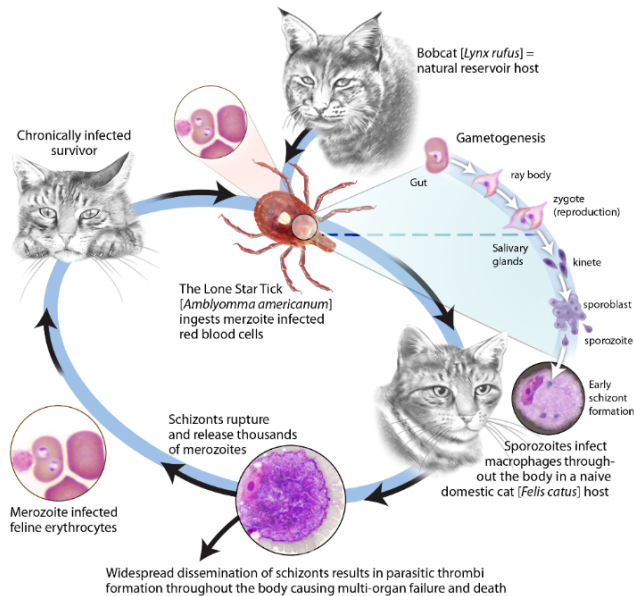


Figure 1: Life cycle of *Cytauxzoon felis*. The acute schizogenous phase is typically fatal in the domestic cat. Hosts that survive develop a chronic erythroparasitemia with merozoite-infected red blood cells that are the basis of cytologic screening. CCAL image from: Tarigo JL, *et al.* (2013).

Interestingly, the pathogenicity of *C. felis* in domestic cats appears to vary between enzootic regions. In the 1990s reports began to emerge of pet cats that survived infection with *C. felis* (Walker *et al.* 1995; Meinkoth *et al.* 2000). These early reports of subclinical disease were from cats that originated in the Ozark Plateau of Arkansas, Missouri, and Oklahoma. A 2007 study of asymptomatic free-roaming cats enrolled in trap-neuter-release (TNR) programs on the east coast and in Tennessee found a low prevalence of subclinical infection, 0.3% (n=961) (Haber *et al.* 2007). More recently, a study in apparently healthy domestic cats in and around the Ozark Plateau of Oklahoma, Arkansas, and Missouri identified an overall disease prevalence of 6.9% (n=902). Within this region, the prevalence of infection ranged from 3.4% in Oklahoma to 12.9% in southern Missouri and 15.5% in northwest Arkansas (Rizzi *et al.* 2015).

The difference in the prevalence of inapparent carriers between the eastern region of the U.S. (0.3%) and the Ozark Plateau (3.4-15.5%) may suggest the existence of a less pathogenic strain of *C. felis* in the Ozark region. To test this hypothesis, molecular studies have explored the genetic variability and revisited the taxonomy of these piroplasms (Brown *et al.* 2010; Shock *et al.* 2012; Schreeg *et al.* 2016; Pollard *et al.* 2017). Other factors may influence the pathogenicity of *C. felis* in domestic cats such as differences in the innate

immunity of the host or the dose of the infectious inoculum. (Tarigo *et al.* 2013). It is possible that a difference in the biology of the tick vector affects the pathogenicity of the parasite. It is also possible that the increasing availability of more sensitive diagnostic tests are simply increasing the frequency of detection of asymptomatic carriers. In a recent review article on cytauxzoonosis in domestic cats, it was suggested that non-fatal, clinically inapparent infections should no longer be considered rare; especially in enzootic regions. (Wang *et al.* 2017). Still, the epidemiology of cytauxzoonosis is complex and gaps in our understanding remain.

The purpose of this study was to measure the prevalence of *C. felis* in apparently healthy feral cats in Russellville Arkansas. Russellville is located in the Arkansas River Valley, adjacent to the Ozark Plateau. Venous blood samples were microscopically evaluated for *C. felis* merozoites and positive samples were submitted for PCR confirmation by a commercial veterinary diagnostic laboratory. Measuring the prevalence of this infection in feral animals may improve our understanding of the epidemiology of this disease and the role of feral cats as a disease reservoir.

Materials and Methods

From April through August 2013, convenience blood samples were obtained from 33 feral cats that were live-trapped as part of a wildlife science graduate study of the feral population in Russellville, Arkansas (Norman 2014). Consistent with institutional requirements at the time, all trapping and handling procedures were performed in accordance with the guidelines of the American Society of Mammalogists (Sikes *et al.* 2011). Briefly, a general exam was performed by the graduate student while the animal was under sedation with dexmedetomidine HCl (Dexdomitor®, Zoetis U.S.A.) The animal's sex, approximate age based on dentition, weight, temperature and body condition score (BCS) were recorded. Additional health information collected included a visual inspection for ectoparasites, external signs of illness such as naso-ocular discharge, or evidence of diarrhea, and evidence of pregnancy or lactation. Approximately 0.5ml of venous blood was collected in lithium heparin, or ethylenediaminetetraacetic acid (EDTA) microvacutainers (Becton Dickenson Co., Franklin Lakes, N.J.). The sedation was reversed with atipamezole HCl (Antisedan®, Zoetis U.S.A) and the animal was released following full recovery. The blood samples

Prevalence of *Cytauxzoon felis* in Feral Cats

were chilled and transported in a cold pack back to the lab where they were used for whole blood analysis for feline leukemia (FeLV) and feline immunodeficiency virus (FIV) as part of the primary research project.

Within 24 hours blood smears were made from the residual blood for cytological screening for *C. felis*. The slides were prepared in triplicate for each sample and air dried prior to staining. Two of the slides were stained with a Romanowsky stain (DipQuik, Jorgenson labs) and the third unstained blood smear was stored for future reference. Stained specimens were examined under oil immersion (1000x) for the presence of *C. felis* merozoites in erythrocytes. Fifty to 75 high power fields (hpf) were examined, focusing on the monolayer region of the smear. The feather edge was also screened for schizonts. Although *C. felis* merozoites may present in several forms, only the signet and 'safety pin' forms were counted. The sample was considered positive if 5 or more affected red blood cells were identified per 50 hpf. This represents an estimated parasitemia of $\geq 0.05\%$; assuming an average of 200 rbc/hpf in the monolayer region of the blood smear.

Samples from the animals that were positive on cytology were submitted for confirmation testing by a commercial veterinary diagnostic laboratory (Idexx laboratories, Westbrook, ME) where unstained blood smears were used for DNA extraction and polymerase chain reaction (PCR) analysis (*C. felis* RealPCR™, Idexx labs). One cytologically negative specimen was also submitted for PCR testing as a negative control.

The overall disease prevalence was calculated as the proportion of the specimens that were positive on both cytology and PCR. Binomial confidence intervals were calculated at the 95% confidence level.

The stated purpose of this study was to identify *C. felis* infections in apparently healthy feral cats. Due to the non-specific signs associated with this disease and the difficulty in assessing these signs in feral animals, the presence of fever ($>102.5^{\circ}\text{F}$) was used as an exclusion criterion for identifying clinically affected animals.

Results

Stained blood smears from 33 feral cats were examined microscopically for the presence of *C. felis* merozoites. Six of the specimens tested positive on cytology. Unstained slides were available for 5 of these samples and they were subsequently submitted for confirmation testing by PCR at a commercial veterinary diagnostic laboratory. Four of the cytologically positive specimens also tested positive on PCR (Table 1). This

indicates an overall prevalence of 13% (CL 95%, CI 3-32)

Three of the animals that tested positive for *C. felis* were afebrile at the time of sample collection. The initial temperature for one animal was not recorded; however, the general exam for that animal was normal. Thus all 4 animals were considered to be inapparent carriers of *C. felis*. All of the infected animals were adults (> 6 months). Three were males and one was a female.

As mentioned earlier, one cytologically negative specimen was also submitted for PCR confirmation as a negative control (not shown in Table 1). This sample tested negative on PCR as well.

Discussion

This study measured the prevalence of *C. felis* in apparently healthy feral cats living in an exurban environment in the Arkansas River Valley. The study area is located adjacent to the Ozark Plateau where cytauxzoonosis is enzootic and the sylvatic reservoir (bobcat) and principal vector (lone star tick) are common. The prevalence of subclinical *C. felis* infection in this population of feral cats was 13% (4/32; CL 95%, 3 - 32). These findings are similar to levels previously reported in free roaming and pet cats from the Ozark Highlands of eastern OK (16.9%, 9.7-27.2), northwest AR (15.3%, 10.3-21.7), and southern Missouri (12.9%, 6.1-24.0) (Rizzi *et al.* 2015).

The prevalence of cytauxzoonosis has been shown to vary within enzootic regions. For example, in central Oklahoma the reported prevalence (3.4%) was lower than that found in eastern Oklahoma (16.9%) (Rizzi *et al.* 2015; Nagamori *et al.* 2016). A recent study utilized an ecological niche model to predict the distribution of *C. felis* in domestic cats in Oklahoma, Missouri, and

Table 1. Results of cytology and PCR diagnostic testing for *Cytauxzoon felis* in 33 feral cats. Overall prevalence (specimens positive on both tests) was 13% (4/32). Note: 5 of 6 samples that were positive on cytology were available for PCR confirmation.

<i>C. felis</i>	Cytology	PCR*	Cytology + PCR
Positive	6	4	4
Negative	27	1	28
Total	33	5	32
Prevalence (95% CL)	18% (7 - 35)		13% (3 - 32)

Arkansas (Mueller *et al.* 2013). The model used confirmed cytauxzoonosis case records, vector and sylvatic reservoir distribution data, and other environmental factors to generate maps that predict high risk areas for *C. felis*. Notwithstanding the author's caution that limited data was available from Arkansas, the model predicted a lower prevalence of disease in the River Valley in Arkansas versus the surrounding highlands of the Ozarks to the north and the Ouachita mountains to the south. The results of the current study would suggest that *C. felis* is more evenly distributed in western Arkansas.

Although health assessment in feral animals is a challenging prospect, a general exam was performed on the sedated animals in this study. None of the animals that tested positive for *C. felis* exhibited fever or other external signs of disease consistent with feline cytauxzoonosis at the time of blood draw. Since inapparent carriers can remain parasitemic for a prolonged period of time, they present an increased risk of infection for naïve free roaming cats and a reservoir of disease in this exurban setting.

In addition to the small sample size in the current study, there are inherent limitations for each of the diagnostic tests used (cytology, PCR) that should be considered when interpreting these results. Cytological screening for merozoites in asymptomatic animals is challenging in part because of the low levels of parasitemia that are commonly encountered. The erythrocytic merozoites of *C. felis* are small (1-2 μm) and are found in several different forms (signet, 'safety pin', punctate). The later can be difficult to distinguish from Howell Jolly bodies, stain precipitate and even drying artifacts (Fig. 2). Further, some of the convenience

blood samples used in this study were originally collected in heparinized tubes. Heparin is not an ideal anticoagulant for examining the morphology of erythrocytes as it can cause cellular distortion and variable stain uptake. Thus cytological screening, although rapid and inexpensive, has limitations. PCR analysis for parasitic DNA is a more sensitive and specific test when compared to cytology. (Birkenheuer *et al.* 2006b). Ideally, all samples (positive and negative on cytology) would be confirmed by PCR. These tests are commercially available but expensive to run and as with any test, false positives and false negatives are possible. In this study, one sample was identified as positive on cytology but tested negative on PCR. Because PCR is a more specific test than cytology, the sample was recorded as negative for *C. felis* (Table 1).

Conclusion

The current study measured a 13% prevalence of *Cytauxzoon felis* infections in apparently healthy feral cats living in Russellville, Arkansas. A comparable level of infection was reported previously in asymptomatic cats in the adjacent Ozark Highlands region (Rizzi *et al.* 2015). Thus, the results of the current study suggest that the distribution of *C. felis* extends into the Arkansas River Valley at a similar level. The relatively high prevalence of *C. felis* reported here also supports the hypothesis that feral cats serve as a reservoir of infection for free roaming, naïve cats in exurban environments where the sylvatic reservoir (bobcat) is less common. Further study of the epidemiology of cytauxzoonosis is needed to assess whether the prevalence of asymptomatic carriers reflects a change in host-parasite interaction.

Acknowledgments

The author is grateful to Ms. Catherine Normand and Dr. Rachael E. Urbanek for providing the convenience blood samples used in this study, to Idexx labs for providing PCR confirmation testing, and to Arkansas Tech University for the laboratory support and funds to defray the cost of publication. The author would also like to thank the anonymous JAAS reviewers for their constructive criticism and suggestions for improving this manuscript.

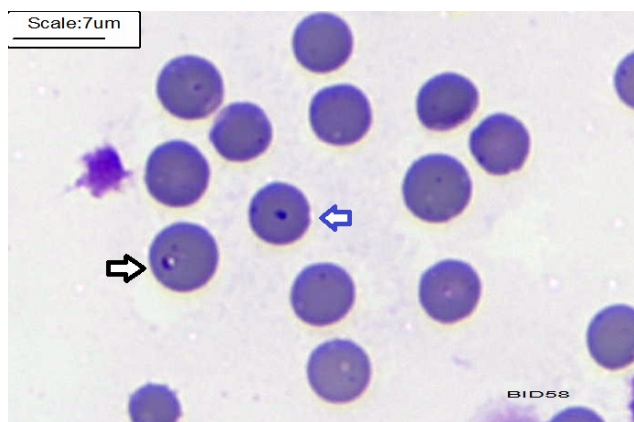


Figure 2. *Cytauxzoon felis* merozoite (black arrow) on a peripheral blood smear. The blue arrow indicates a Howell Jolly body. Blood is stained with a Romanowski differential stain (DipQuik). Oil (1000x).

Prevalence of *Cytauxzoon felis* in Feral Cats

Literature Cited

- Alvarado-Rybak M, L Solano-Gallego, and J Millán.** 2016. A review of piroplasmid infections in wild carnivores worldwide: importance for domestic animal health and wildlife conservation. *Parasites & Vectors* 9:538.
- Birkenheuer AJ, JA Le, AM Valenzisi, MD Tucker, MG Levy, and EB Breitschwerdt.** 2006a. *Cytauxzoon felis* infection in cats in the Mid-Atlantic States: 34 Cases (1998-2004). *Journal of the American Veterinary Medical Association* 228:568-571.
- Birkenheuer AJ, H Marr, AR Alleman, MG Levy, and EB Breitschwerdt.** 2006b. Development and evaluation of a PCR assay for the detection of *Cytauxzoon felis* DNA in feline blood samples. *Veterinary Parasitology* 137:144-149.
- Birkenheuer AJ, HS Marr, C Warren, AE Acton, EM Mucker, JG Humphreys, and MD Tucker.** 2008. *Cytauxzoon felis* infections are present in bobcats (*Lynx rufus*) in a region where cytauxzoonosis is not recognized in domestic cats. *Veterinary Parasitology* 153:126-130.
- Brown HM, KS Latimer, LE Erikson, ME Cashwell, JO Britt, and DS Peterson.** 2008. Detection of persistent *Cytauxzoon felis* infection by polymerase chain reaction in three asymptomatic domestic cats. *Journal of Veterinary Diagnostic Investigation* 20:485-488.
- Brown HM, JM Lockhart, KS Latimer, and DS Peterson.** 2010. Identification and genetic characterization of *Cytauxzoon felis* in asymptomatic domestic cats and bobcats. *Veterinary Parasitology* 172:311-316.
- Cohn LA, AJ Birkenheuer, JD Bruner, ER Ratcliff, and AW Craig.** 2011. Efficacy of atovaquone and azithromycin or imidocarb dipropionate in cats with acute cytauxzoonosis. *Journal of Veterinary Internal Medicine* 25:55-60.
- Haber MD, MD Tucker, HS Marr, JK Levy, J Burgess, MR Lappin, and AJ Birkenheuer.** 2007. The detection of *Cytauxzoon felis* in apparently healthy free-roaming cats in the U.S.A. *Journal of Veterinary Parasitology* Vol. 146:316-320.
- McAllister CT, LA Durden, and HW Robison.** 2016. The ticks (Arachnida: Acari: Ixodida) of Arkansas. *Journal of the Arkansas Academy of Sciences* 70:141-154.
- Meinkoth J, AA Kocan, L Whitworth, G Murphy, JC Fox, and JP Woods.** 2000. Cats surviving natural infection with *Cytauxzoon felis*: 18 cases (1997–1998). *Journal of Veterinary Internal Medicine* 14:521-525.
- Mueller EK, KA Baum, M Papeş, LA Cohn, AK Cowell, and MV Reichard.** 2013. Potential ecological distribution of *Cytauxzoon felis* in domestic cats in Oklahoma, Missouri, and Arkansas. *Veterinary Parasitology* 192:104-110.
- Nagamori Y, JE Slovak, and MV Reichard.** 2016. Prevalence of *Cytauxzoon felis* infection in healthy free-roaming cats in north-central Oklahoma and central Iowa. *Journal of Feline Medicine and Surgery Open Reports* 2:1-4.
- Norman C.** 2014. Feral cat population dynamics, multi-scale habitat selection, and disease prevalence in an exurban landscape. [MS thesis]. Russellville (AR): Arkansas Tech University. 114 p.
- Pollard DA, MV Reichard, LA Cohn, AM James, and PJ Holman.** 2017. Genetic variability of cloned *Cytauxzoon felis* ribosomal RNA ITS1 and ITS2 genomic regions from domestic cats with varied clinical outcomes from five states. *Veterinary Parasitology* 244:136-143.
- Reichard MV, JH Meinkoth, AC Edwards, TA Snider, KM Kocan, EF Blouin, and SE Little.** 2009. Transmission of *Cytauxzoon felis* to a domestic cat by *Amblyomma americanum*. *Veterinary Parasitology* 161:110-115.
- Rizzi TE, MV Reichard, LA Cohn, AJ Birkenheuer, JD Taylor, and JH Meinkoth.** 2015. Prevalence of *Cytauxzoon felis* infection in healthy cats from enzootic areas in Arkansas, Missouri, and Oklahoma. *Parasites & Vectors* 8:13.
- Schreeg ME, HS Marr, JL Tarigo, LA Cohn, DM Bird, EH Scholl, MG Levy, et al.** 2016. Mitochondrial genome sequences and structures aid in the resolution of *Piroplasmida* phylogeny. *PLoS ONE* 11: e0165702.
- Shock BC, SM Murphy, LL Patton, PM Shock, C Olfenbittel, J Beringer, S Prange, et al.** 2011. Distribution and prevalence of *Cytauxzoon felis* in bobcats (*Lynx rufus*), the natural reservoir, and other wild felids in thirteen states. *Veterinary Parasitology* 175:325-330.

- Shock BC, AJ Birkenheuer, LL Patton, C Olfenbittel, J Beringer, DM Grove, M Peek, et al.** 2012. Variation in the ITS-1 and ITS-2 rRNA genomic regions of *Cytauxzoon felis* from bobcats and pumas in the eastern United States and comparison with sequences from domestic cats. *Veterinary Parasitology* 190:29-35.
- Sikes RS, WL Gannon, and the Animal Care and Use Committee 1 of the American Society of Mammalogists.** 2011. Guidelines of the American Society of Mammalogists for the use of wild mammals in research. *Journal of Mammalogy* 92:235-253.
- Tarigo JL, EH Scholl, DM Bird, CC Brown, LA Cohn, GA Dean, MG Levy, et al.** 2013. A Novel candidate vaccine for cytauxzoonosis inferred from comparative Apicomplexan genomics. *PloS One* 8: e71233.
- Wagner JE.** 1976. A fatal cytauxzoonosis-like disease in cats. *Journal of the American Veterinary Medical Association.* 168:585-588.
- Walker DB and RL Cowell.** 1995. Survival of a domestic cat with naturally acquired cytauxzoonosis. *Journal of the American Veterinary Medical Association* 206:1363-1365.
- Wang JL, TT Li, GH Liu, XQ Zhu, and C Yao.** 2017. Two tales of *Cytauxzoon felis* infections in domestic cats. *Clinical Microbiology Reviews* 30:861-884.
- Zieman EA, FA Jiménez, and CK Nielsen.** 2017. Concurrent examination of bobcats and ticks reveals high prevalence of *Cytauxzoon felis* in Southern Illinois. *Journal of Parasitology* 103:343-348.